

# Artefacts on mammograms: recognition, causes and prevention.

Hrovat Polona<sup>1</sup>, Knez Sabina<sup>1</sup>, Kramer Maša<sup>1</sup>, Nusdorfer Ela<sup>1</sup>, Sember Tara<sup>1</sup>, Gošnak Dahmane Raja<sup>1</sup>  
<sup>1</sup>University of Ljubljana, Faculty of Health Sciences, Ljubljana, Slovenia  
 Contact: Raja Gošnak Dahmane: raja.dahmane@zf.uni-lj.si

## ABSTRACT

Digital mammography represents the foundation of modern screening and diagnostic strategies for breast cancer detection, as it enables high resolution imaging, precise visualization of tissue structures, and early identification of pathological changes.

Mammography is an imaging method that uses low-dose x-rays to create detailed pictures of the breast. Mammograms are performed in at least two standard views, the craniocaudal view (CC) and the mediolateral oblique (MLO).

The recognition and prevention of artefacts in mammography is a crucial role in ensuring accurate detection of breast pathology. Artefacts can be divided into four main groups: patient related, detector based, equipment related and post-acquisition related.

## METHODS

A systematic analysis of scientific literature was conducted for the review, published between 1995 and 2025 was conducted, with emphasis on studies addressing artefacts in digital mammography, contrast-enhanced mammography, and methods for their detection, classification, and clinical management.

Included were articles describing the technical mechanisms underlying artefact formation, their impact on diagnostic image quality, and contemporary approaches to artefact reduction, including artificial intelligence algorithms and transfer learning techniques and what we can do to prevent them.

## CONCLUSION

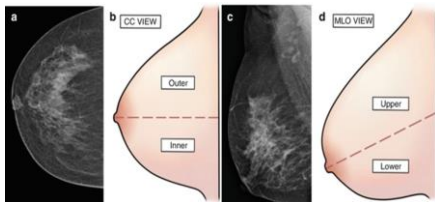
Artefacts in mammography represent a significant challenge in breast imaging, as they can obscure pathology or produce false results, potentially leading to diagnostic errors. Artefacts can arise from patient-related factors, equipment issues, and technique-dependent processes, with each contributing in its own way to reduced image quality and diagnostic reliability.

Effective recognition of artifacts requires a combination of clinical experience, technical knowledge, and attention to detail from both radiographers and radiologists. Overall, maintaining high diagnostic accuracy, reducing unnecessary repeat examinations, and improving breast cancer detection outcomes critically depend on heightened awareness, preventive strategies, and careful artifact recognition.

## RESULTS

Screening mammograms are performed in at least two standard views, which include the craniocaudal view (CC) and the mediolateral oblique (MLO).

By comparing these two different viewpoints, structures that are superimposed upon one another in one view may be separated in the other.



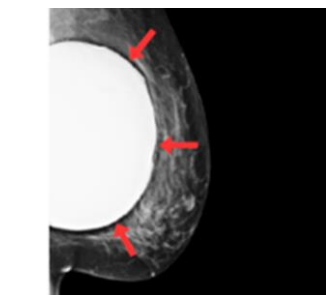
**Figure 1:** Standard views in mammography. On the left two pictures (a and b) is represented craniocaudal view (CC), while the right two pictures show (c and d) mediolateral oblique view (MLO) (Radiological Anatomy, 2023).

**Artefacts on mammograms:** artifacts reduce quality of mammograms and can create pseudolesions or mask abnormalities leading to misinterpretation. Radiographers are the first to encounter patients and perform the examination, so it is important that they know how to recognize artifacts in images, understand why they occur, and know how to reduce or prevent them if possible. Artefacts can be patient related (patient motion, superimposition of objects or other parts of the body over the breast), detector based (dead pixels, dead or unread lines, ghosting), equipment related (other components on the gantry) or post acquisition related (failure to properly reconstruct the image at the review station or inability of the processing algorithm to compensate for differences in exposure across the detector).

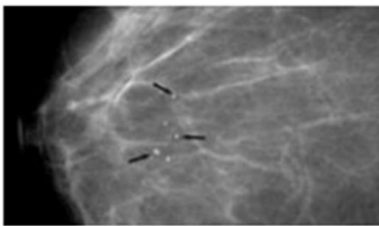
**Artefact recognition:** Different artefacts show in different ways, but they do have one thing in common and that is, that they remain stable with repeated imaging.

### Causes of artefacts:

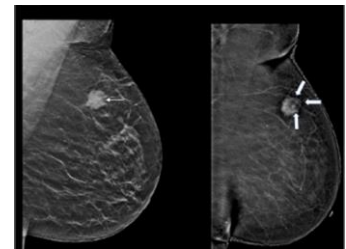
Artefacts on mammogram can be caused by various factors. Patient-related artefacts arise from physical factors external to the imaging system.



**Figure 2:** Breast implant, where can be seen that we have an obscured view of surrounding tissue. Because of the higher attenuation of x-ray photons in the breast implant, the overall quality of the mammogram is not as good (Singla et al, 2025).



**Figure 3:** Artefacts caused by dust and dirt that mimic calcifications (Singla et al, 2025).



**Figure 4:** Rim artefact. Left side shows contrast enhanced mammography, mediolateral view (MLO), low energy image, showing high-density mass with spiculated margin (white arrow). Right side, recombined image, the mass shows heterogeneous post contrast enhancement with surrounding rim artefact (white block arrows), seen as black line around the mass (Singla et al, 2025).

### Prevention on artefacts

Artefacts are not that hard to prevent if we take the correct protocols. Patient-related artefacts are prevented by removing clothing and hair, careful positioning and good compression, as it disables motion. Patients should not use antiperspirant on exam day and should clean axilla prior to imaging to prevent antiperspirant artefacts. When imaging patients with breast implants Eklund's technique ought to be used and magnetic resonance imaging (MRI) is preferred.

Equipment-related artefacts that occur due to x-ray tube malfunction may be prevented with daily check-ups and weekly gain calibrations, since the issue can be spotted during the quality control tests. Artefact caused by dirt or dust can be avoided with visual inspection of detector/film surface and regular cleaning. Dual-energy artefact, which belongs to the technique-dependant artefacts can be averted with the proper timing between low-energy and high-energy image captures and correct exposition parameters. Rim artefact in CEMM is trickier to prevent as it needs update software and good post-processing.

## REFERENCES

- Bassett L. W. (1995). Clinical image evaluation. *Radiologic clinics of North America*, 33(6), 1027-1039.
- Chaloevitthi, I., & Mutarak, M. (2016). Artefacts in mammography: way to identify and overcome them. *Singapore medical journal*, 47, 634-641. <https://pubmed.ncbi.nlm.nih.gov/16810441/>
- Chaloevitthi, I., Mutarak, M., & Ng, K. H. (2016). Artefacts in mammography: ways to identify and overcome them. *Singapore medical journal*, 47(7), 634-641. <https://pubmed.ncbi.nlm.nih.gov/16810441/>
- Choi, J., Kim, J., Kang, B. I., Choi, B. C., Song, B., & Yang, H. (2014). Mammographic artifacts on full-field digital mammography. *Journal of digital imaging*, 27(2), 231-236. <https://doi.org/10.1007/s10278-013-9641-4>
- D'Orsi, C. (2006). DMIST: digital mammography in the USA. *Breast Cancer Research*, 8(5). <https://doi.org/10.1186/bcr1419>
- Geiser WR. *Artifacts in digital mammography*. In: Whitman GJ, Hargrove TM, eds. *Digital Mammography: A Practical Approach*. Cambridge University Press; 2012:73-84.
- Guanaisi, H. (2023). *Radiological Anatomy*. In: Dev, B., Joseph, L.D. (eds) *Holistic Approach to Breast Disease*. Springer, Singapore. [https://doi.org/10.1007/978-981-99-0035-0\\_2](https://doi.org/10.1007/978-981-99-0035-0_2)
- National Cancer Institute. (2025). Mammography. In *NCI Dictionary of Cancer Terms*. <https://www.cancer.gov/publications/dictionaries/cancer-terms/def/mammography>
- Noel, J., Gill, M. K., Vignoli, C., Bicchieri, C., De Benedetto, D., Di Naro, F., Vaziri, E., Berti, C., & Miele, V. (2020). Artefacts in contrast-enhanced digital mammography: how can they affect diagnostic image quality and confuse clinical diagnosis? *In Insights into Imaging* (Vol. 11, Issue 1). Springer. <https://doi.org/10.1186/s13244-019-0811-x>
- Oza, P. R., Sharma, P., & Patel, S. (2022). Transfer learning-assisted classification of artifacts removed and contrast-improved digital mammograms. *Scalable Computing: Practice and Experience*, 23(1), 115-127. <https://doi.org/10.12694/scpe.v23i1.1992>
- Perič, D., & Breg, E. R. (2024). *Univerza v Ljubljani zdravstvena fakulteta radiološka tehnologija 1*. Stopnja the impact of cardiovascular implantable electronic devices on the execution and quality of mammographic images-literature re-view. Diploma work.
- Prado, C., Kim, J., Monto, M., Chadd, M. J., Fernandez, J., Viana, E., & Arzooq, J. (2013). Experience in real-analysis for digital mammography at a university hospital. *Radiation protection dosimetry*, 165(1-4), 354-358. <https://doi.org/10.1093/rpd/nct082>
- Reeves, R. A., & Kaufman, T. (2023). *Mammography*. StatPearls Publishing. <https://www.ncbi.nlm.nih.gov/books/NBK559510/>
- Schaeppert, A., Glocker, B., Rosenhewitz, M. (2023). Radio-Opaque Artefacts in Digital Mammography: Automatic Detection and Analysis of Downstream Effects. 2025 IEEE 22nd International Symposium on Biomedical Imaging (IS-BI). DOI: <https://doi.org/10.1109/ISBI66581.2025.10981239>
- Singla, V., Garg, D., Bhambhani, N. P. (2025). Optimizing contrast-enhanced mammography: A comprehensive review of artifacts, causes, and remedies. *Current Problems in Diagnostic Radiology*. DOI: <https://doi.org/10.1097/cpr.0000000000000101>
- Tekcan-Sani, D. E., & Sanli, A. N. (2025). Artefacts in contrast-enhanced mammography and the clinical management. *Clinical Radiology*, Volume 9, 107084. DOI: <https://doi.org/10.1016/j.crad.2025.107084>
- Wang, Y. T., Yang, S., Leung, P. W., Chow, D. L. Y., Kwok, K. Y., Lau, Y. K., & Li, C. A. (2025). Artefacts and diagnostic pitfalls in contrast-enhanced mammography: a pictorial review. *In Clinical Radiology* (Vol. 81). W.B. Saunders Ltd. <https://doi.org/10.1016/j.crad.2024.106763>
- World Health Organization. (2014). WHO position paper on mammography screening. <https://www.ncbi.nlm.nih.gov/books/NBK269545/>
- Yagil, Y., Shalom, A., Rundstein, A., Servadio, Y., Halshok, O., Goflich, M., Sklair-Levy, M. (2016). Challenges in contrast-enhanced spectral mammography interpretation: artifacts lexicon. *Clinical Radiology*, Volume 71, issue 5; pages 450-457.